

TEOXANE

TEOXANE



THE
EXPERT
CASE
BOOK # 4

LIP REJUVENATION
AND ENHANCEMENT

TEOSYAL RHA® 1/2/3
TEOSYAL PURESSENSE KISS®

CLINICAL CASES

With the TEOXANE LipUnique Collection

1 **PROF. GIUSEPPE SITO**
p. 8

"The lips have always been a symbol of sensuality and attractiveness in women. Indeed, the lips are one of the areas of the face that draw most attention and contribute significantly to facial harmony and beauty. Moreover, the lips are central to both verbal and non-verbal communication – whether through words or facial expressions, the lips enable women of all ages to express their feelings and personality. Thus, it is not surprising that women cherish the beauty of their smile regardless of their age.

2 **DR. PATRICK TRÉVIDIC**
p. 12

3 **DR. RAYMOND WU**
p. 16

As an aesthetic physician and surgeon, I have noticed an increasing demand for more attractive lips from women of all ages. In general, younger patients seek full, naturally plump lips while patients with ageing lips wish to restore lost volume and re-establish their natural, youthful lip shape. As the needs vary substantially between individual patients, I apply my anatomy knowledge and injection technique skills to select tailored treatments for any single patient.

4 **DR. RAUL CETTO**
p. 20

5 **DR. RAUL CETTO**
p. 24

When assessing treatments for the highly dynamic perioral area, in addition to the technique and the right injection level, I believe it is key to choose dermal fillers that can accompany and respect natural lip movements, which is fundamental to achieving natural-looking results. For this reason, I prefer to use dermal fillers from the TEOXANE LipUnique Collection, which provides me with a comprehensive toolkit to address the different needs of my patients.

Thanks to the balance between the stretch and volumizing capacities across the TEOXANE lip fillers, I can select the most appropriate product for any indication in this dynamic facial area. Based on my personal experience, I recommend the very high stretch capacity of RHA® 1 to fill fine, dynamic perioral lines, such as barcode wrinkles. To achieve natural-looking lip eversion, I rely on the high malleability of RHA® 2, which enables easy filler positioning and moulding under the labial mucosa.

In this TEOXANE CASEBOOK n°3, my colleagues and I aim to share our best practice to achieve predictable and natural-looking lip treatment outcomes. We hope our knowledge in this field will help you enhance your own approach and provide you with useful principles to select optimal, personalized treatments for your patients."

Dr Patrick Trévidic, France

TEOXANE Chief Scientific Officer

THE TEOXANE APPROACH

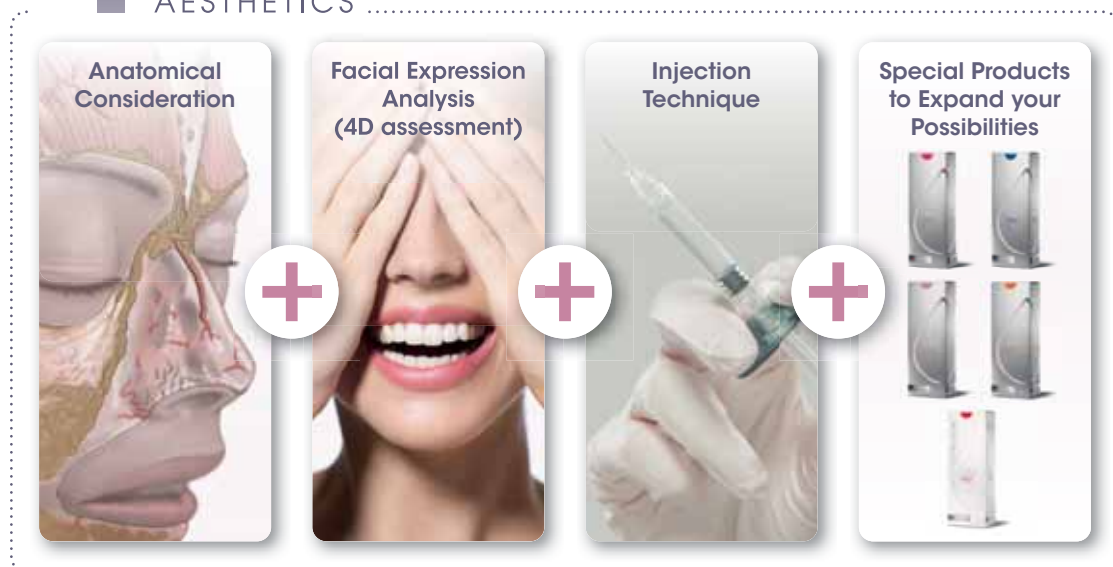

Consistently with patient expectations, the current trend in aesthetic medicine is to obtain natural-looking and balanced outcomes.¹ To do so, it is essential prior to any treatment to perform full face assessment based on a sound understanding of facial anatomy as well as a deep knowledge of the dynamic movements of the face, which constitutes the fourth dimension of aesthetic treatments:¹ a **4D assessment**.

When it comes to hyaluronic acid (HA) filler injections, practitioners must also select an adapted and efficient technique to inject the filler in the right location to enable it to follow the natural movements of the face. To this purpose, it will be important to choose HA fillers with appropriate rheological characteristics.

The TEOXANE APPROACH has been developed to allow physicians to get optimized results based on these principles:

A 4TH DIMENSION IN FACIAL AESTHETICS



Working with your expertise and the TEOXANE APPROACH, the TEOXANE LipUnique Collection allows you to perform optimal lip treatment by combining the right products at the right injection depth with the appropriate injection technique. This gives you the flexibility to offer your patients predictable, natural-looking and unique results while preserving the dynamic movements of the lips and smile area.^{2,3*}

*Study report 1820.TEOSYAL® RHA keeps its mechanical properties on a large range of stress – Rheological properties of the RHA dermal fillers range. Data on file.

TEOXANE LIPUNIQUE COLLECTION

The TEOXANE LipUnique Collection provides a truly flexible toolkit, allowing you to create bespoke, natural-looking and dynamic lip treatment solutions for your patients.^{2,3}



Correction of dynamic perioral rhytids & barcode lines

- HMW-HA* concentration: 15 mg/mL
- MoD†: ~1.9%
- Box contains: 2 x 1 mL



Dynamic lip reshaping

- HMW-HA* concentration: 23 mg/mL
- MoD†: ~3.1%
- Box contains: 2 x 1 mL



Dynamic lip volumization

- HMW-HA* concentration: 23 mg/mL
- MoD†: ~3.6%
- Box contains: 2 x 1 mL



Pronounced lip volumization

- HMW-HA* concentration: 25 mg/mL
- MoD†: ~8%
- Box contains: 2 x 1 mL

*HMW-HA, high-molecular weight hyaluronic acid. †MoD, degree of modification. Average measurements.

TEOSYAL RHA® 1 to 3, and TEOSYAL PURESENSE KISS® are trademark of the firm TEOXANE SA. These products are gels that contain hyaluronic acid, and 0.3% by weight of lidocaine hydrochloride (local anesthetic can induce a positive reaction to anti-doping tests). In the case of known hypersensitivity to lidocaine and/or amide local anaesthetic agents, we recommend not use lidocaine-containing products - please refer to products without lidocaine. TEOSYAL PURESENSE KISS® also exists without lidocaine: TEOSYAL KISS®.

They are class III medical device and are regulated health product bearing the CE marking (CE2797) under this regulation. For professional use only. Please refer to instructions for use. The product availability depends on registration, please contact your local distributor. Please inform the manufacturer TEOXANE of any side effects or any claim as soon as possible to the following address: medical@teoxane.com

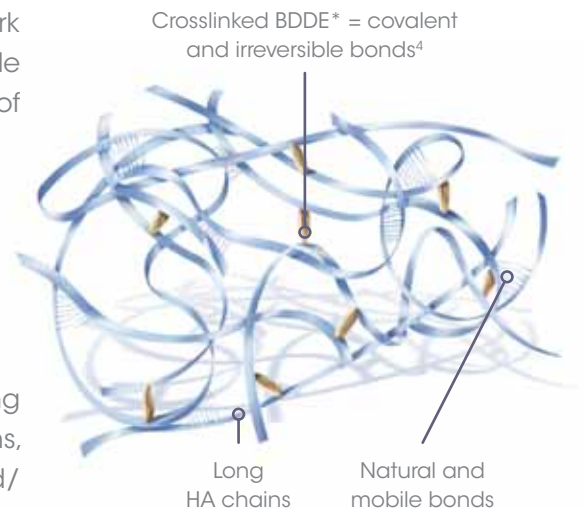
THE SCIENCE BEHIND THE LIPUNIQUE COLLECTION



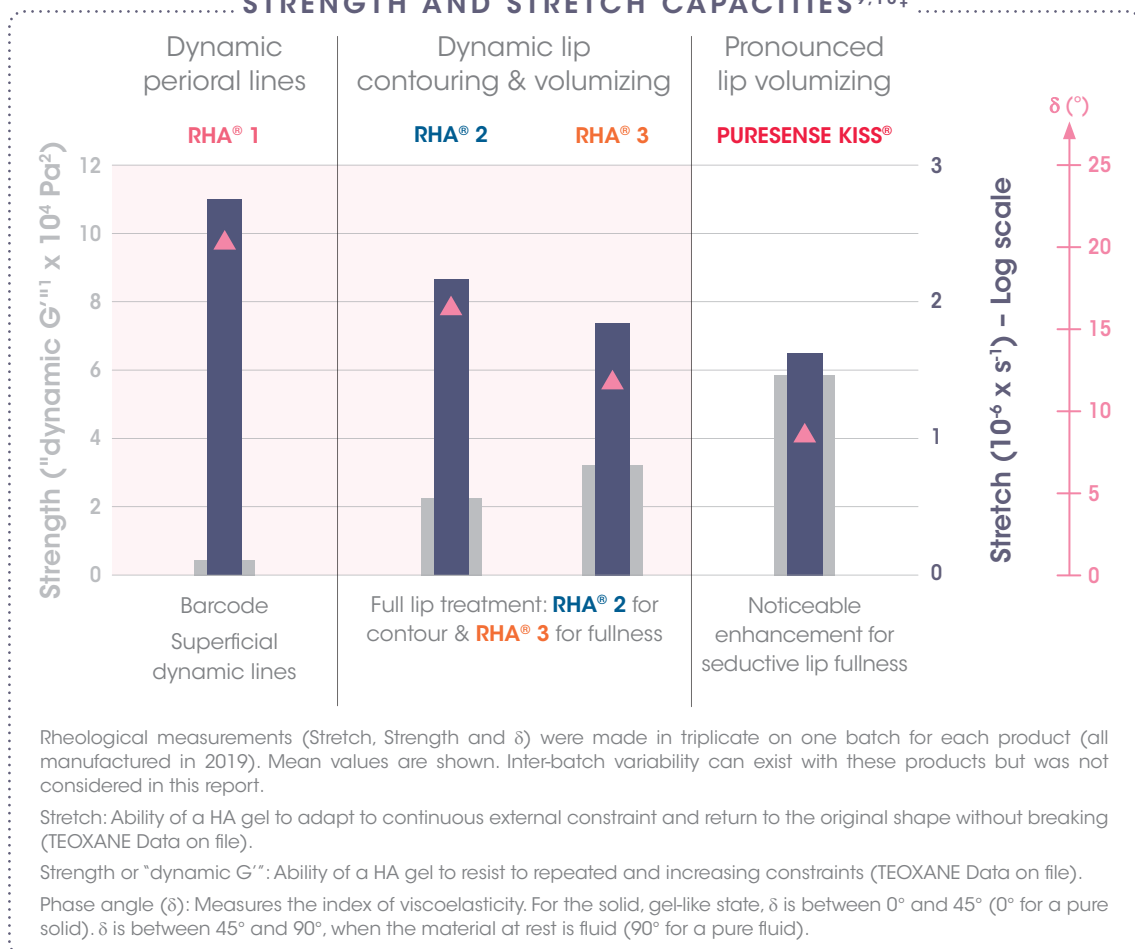
TEOXANE's unique Preserved Network Technology (PNT) allows malleable and dynamic gels reminiscent of natural HA.

- Long HA chains
- Preserved natural and mobile interactions among long HA chains
- Low amounts of crosslinked BDDE required*†
- Low MoD (~1.9–4.0%)†

TEOXANE developed an exclusive method for assessing the behaviour of HA gels under dynamic conditions, including determination and analysis of their Stretch and/ Strength properties.



A PORTFOLIO OF HMW-HA GELS WITH UNPARALLELED STRENGTH AND STRETCH CAPACITIES^{9,10‡}





HA, hyaluronic acid. HMW, high-molecular weight. MoD, degree of modification. RHA[®] 1 = TEOSYAL RHA[®] 1; RHA[®] 2 = TEOSYAL RHA[®] 2; RHA[®] 3 = TEOSYAL RHA[®] 3; PURESENSE KISS[®] = TEOSYAL PURESENSE KISS[®].

*Crosslinked BDDE = BDPE = 1,4-butanediol di-(propan-2,3-diyl) ether. †DoF: Measurement by an independent laboratory of the HA Degree of Modification by 1H NMR. ‡DoF: TEOSYAL RHA[®] keeps its mechanical properties under a large range of strain or stress constraints ("dynamic G''"). Report on the rheological characterization of hyaluronic acid gels.

LIPUNIQUE COLLECTION PRODUCT PROPERTIES


	TEOSYAL RHA® 1 	TEOSYAL RHA® 2 
Intended use	For correction of dynamic perioral lines such as rhytids and barcode lines*†	For dynamic lip reshaping*‡
HA concentration	15 mg/mL	23 mg/mL
Lidocaine concentration	0.3%	0.3%
Technology	Preserved Network Technology	Preserved Network Technology
Composition	Mix of crosslinked & non-crosslinked HMW-HA	Crosslinked HMW-HA
Degree of modification	~1.9%	~3.1%
Rheological properties	Very high Stretch	High Stretch & medium Strength
Depth of injection	Superficial to mid dermis	Into the mucosa to treat lips or mid dermis to correct skin wrinkles/lines
Provided needle	30G 1/2"	30G 1/2"
Packaging	2 x 1 mL	2 x 1 mL

*TEOSYAL RHA® 1, 2, 3. Instructions for use. †DoF: Clinical study TEO-RHA-1501. CSR v0.5. 12 month randomized, placebo-controlled trial of TEOSYAL RHA 1 (n=150) or No-Treatment (n=51) in patients with moderate/severe perioral lines (mean age of 61.6 ± 7.2; 98% female; 96% Caucasian). ‡Post Market Survey (PMS) 2018; RHA range.

	TEOSYAL RHA® 3	TEOSYAL PURESENSE KISS®
		
Intended use	For dynamic lip volumization*‡	For pronounced lip volumization**
HA concentration	23 mg/mL	25 mg/mL
Lidocaine concentration	0.3%	0.3% Also available without lidocaine (TEOSYAL KISS®)
Technology	Preserved Network Technology	PureSense Technology
Composition	Crosslinked HMW-HA	Crosslinked HMW-HA
Degree of modification	~3.6%	~8%
Rheological properties	Medium Stretch & high Strength	Highly cohesive with good projection power
Depth of injection	Into the mucosa to treat lips or deep dermis to correct skin wrinkles	Into mucosa to treat lips or deep dermis to correct skin wrinkles
Provided needle	27G 1/2"	27G 1/2"
Packaging	2 x 1 mL	2 x 1 mL

*Post Market Survey (PMS) 2018; PureSense Range.

PROF. GIUSEPPE SITO



Prof. Giuseppe Sito, MD PhD, is a professor at the School of Aesthetic Medicine Fatebenefratelli Hospital Foundation, Rome and an external adviser for the Postgraduate Course for Aesthetic Medicine Agorà, Milano. He is also a forensic consultant in Aesthetic Medicine for the Court of Naples. Currently, he is Scientific Director of the Aesthetic Masters at Pegaso University (Naples, Italy). After completing his specialization with honors in Surgery and in Endocrine surgery in Naples and earning a degree in Urology at the Catholic University of the Sacred Heart in Rome, his increasing interest in Aesthetic Medicine and Surgery brought him to France for training purposes. He subsequently became a member of the French and Italian Societies of Plastic, Reconstructive and Aesthetic Surgery and of the American Association of Facial Plastic Surgery. Professor Sito has received a Lifetime Achievement Award in Cosmetic Surgery. He has published in international journals and has been an invited speaker at many international congresses and meetings.

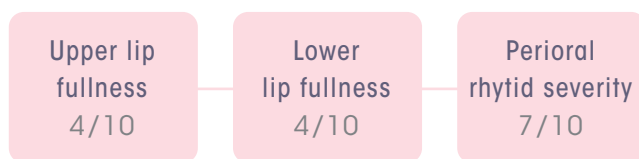PATIENT INFORMATION

Gender: Female
Ethnicity: Caucasian
Age: 62 years old
Fitzpatrick skin type score: I
Photo-ageing: Advanced perioral photo-ageing
Skin quality description (white and red lips): Non-smoker
Previous treatment(s) in the perioral area: None

PATIENT REQUEST

Reduce perioral wrinkles and have better definition of the lips' contour.

BASELINE LIP EVALUATION



Static lip assessment: Thin lips with moderate perioral wrinkles, elongated philtrum (18 mm).

Dynamic lip assessment: Worsening of the perioral rhytids and wrinkles in animation.

10-point scales were used to assess baseline lip evaluations and patient feedback.

PROTOCOL & INJECTION TECHNIQUES

Aim of treatment: Perioral rejuvenation through 1) smoothing of perioral rhytids and wrinkles and 2) shortening the philtrum length for younger-looking lips.

Product of choice: RHA 1 as it is a soft and smooth HA dynamic filler able to easily adapt to facial movements and give a subtle lift to the upper lip, ideal for fine lines, dynamic wrinkles and superficial treatments.

PERIORAL AREA

Location

- 1) Perioral fine lines (cutaneous upper lip)
- 2) Philtrum area

Injection technique

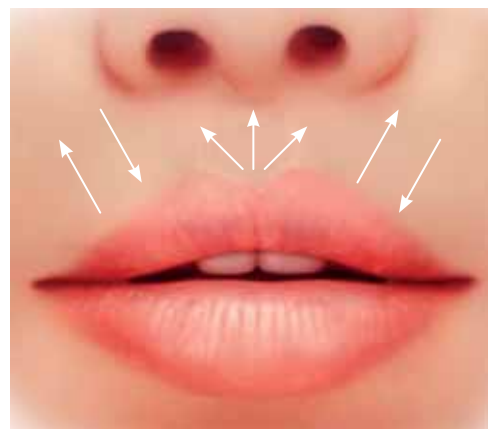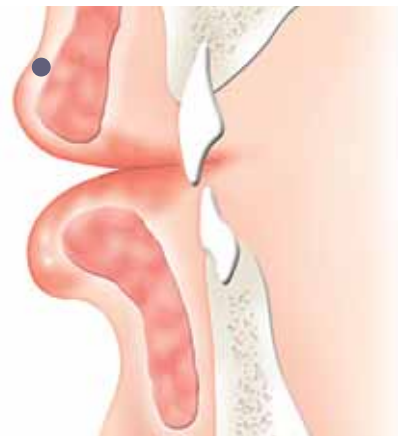- 1) Perioral fine lines (linear injection, no blanching technique):
 - Linear retrograde injection along the rhytids
 - Very superficial, over the muscle
 - On the white lip area the treatment must cover the entire area from vermillion to the nose or *vice versa* depending on the wrinkles' features
- 2) Philtrum area:
 - Filler injection from the vermillion to the nose and from the Cupid's bow to the philtrum columns (at a 45-degree angle)

Product and volume

- RHA 1
- 1 mL (0.1-0.15 mL for each wrinkle), depending on the number and depth of wrinkles

Needle and injection device

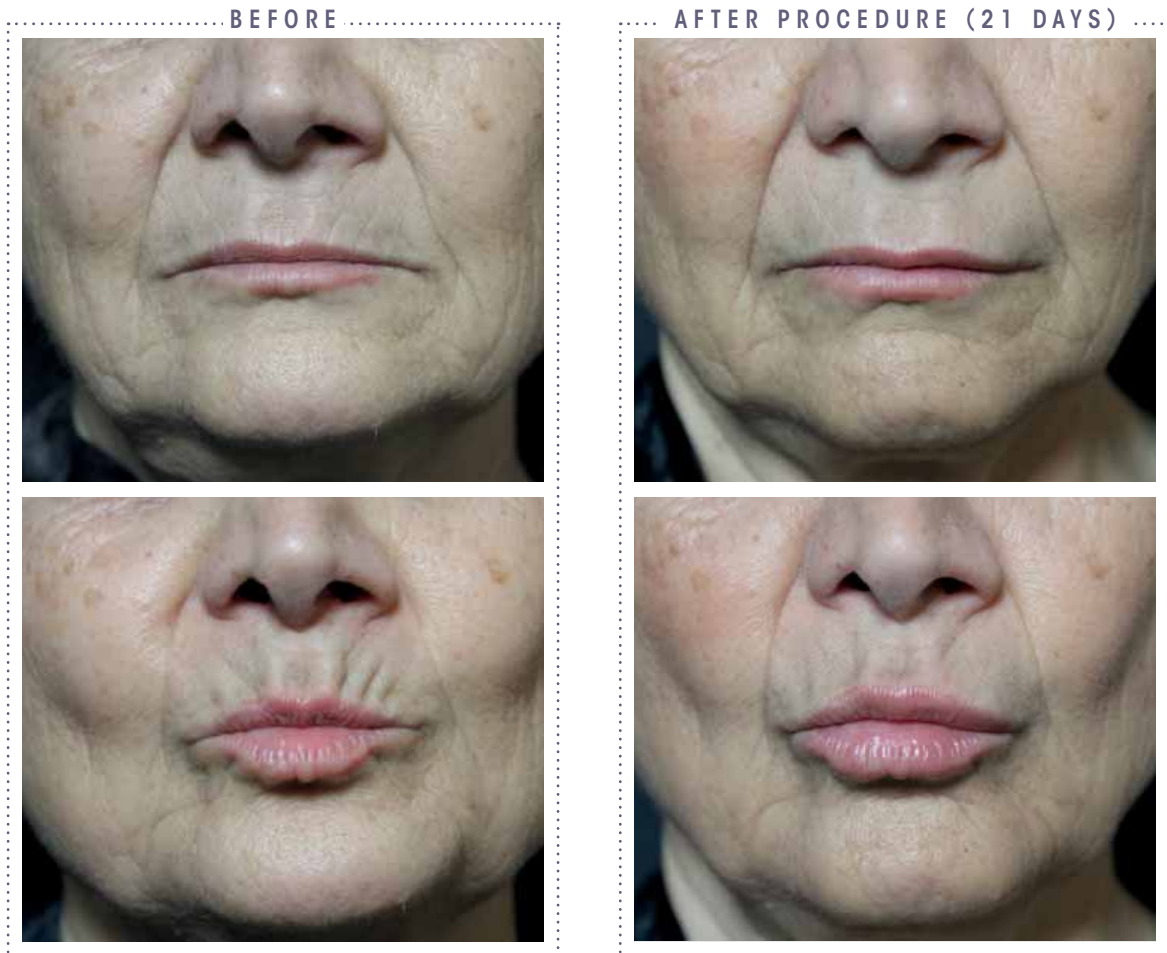- Needle 30G 14 mm with TEOSYAL® PEN (low speed)



CASE 1

Prof. Giuseppe Sito

RESULTS



An immediate, very slight oedema lasted 2-3 hours, no redness, bruising or additional complications.

Follow up after 3 weeks: No touch up.



PATIENT FEEDBACK



The patient returned to daily activities immediately after procedure. The patient was very satisfied with the natural and visible result, particularly the visible distension of the perioral fine lines and mild shortening of the white lip. Her lips were more hydrated and defined. The patient is willing to be injected with the same product again.

PHYSICIAN FEEDBACK

For the next treatment, Professor Sito suggests a reshaping of the lips' profile and increase of lip volume with RHA 2/RHA 3.

DR. PATRICK TRÉVIDIC



Patrick Trévidic, MD, is a plastic, reconstructive and aesthetic surgeon based in Paris, France, and Chairman of the Surgery Department at Sainte-Anne Hospital. He has been instrumental as a key investigator in several anti-ageing studies, and remains to date at the forefront of many others. He has published more than 50 scientific articles in various periodicals and international journals and is often invited to present his work at international congresses worldwide. As well as serving as Scientific Director for the Expert2Expert Medical Publishing Group (www.expert2expert.co.uk), he is also Scientific Director of the largest European Aesthetic Congress, FACE 2 F.A.C.E. Between 2010 and 2014, Dr Trévidic directed and published 3 books on anatomy and aesthetic medicine including the best-seller *Anatomy and Lip Enhancement*. Dr Trévidic is a professor and lecturer on surgery at several universities and schools of medicine in France and abroad.

PATIENT INFORMATION

Gender: Female
Ethnicity: Caucasian
Age: 52 years old
Fitzpatrick skin type score: I
Photo-ageing: Moderate
Skin quality description (white and red lips):
Some fine lines
Previous treatment(s) in the perioral area:
None

PATIENT REQUEST

Lip rejuvenation and beautification.

BASELINE LIP EVALUATION

Upper lip
fullness
3/5

Lower
lip fullness
3/5

Perioral
rhytid severity
2/5

Static lip assessment: Moderate lips with perioral lines.

Dynamic lip assessment: Huge worsening of the lines in animation.

10-point scales were used to assess baseline lip evaluations and patient feedback.

PROTOCOL & INJECTION TECHNIQUES

Aim of treatment: Eversion of the upper and lower lip and correction of perioral wrinkles.

Product of choice: RHA 2 was chosen for its high Stretch, which enables easy positioning and moulding of the filler under the labial mucosa to obtain a natural-looking lip eversion. As this filler contains lidocaine, the procedure is painless and the injection comfortable for the patient.

UPPER LIP AND LOWER LIP EVERSION

Injection technique

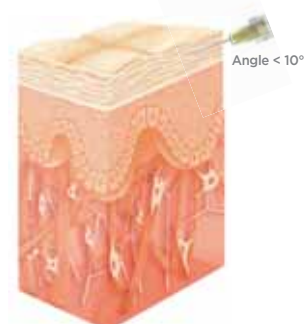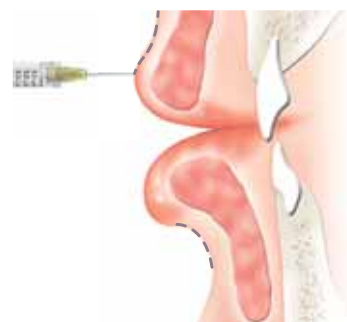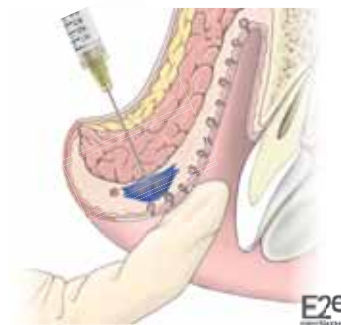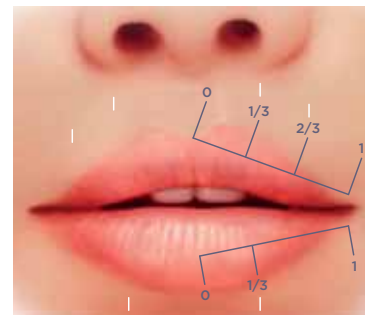
- French kiss technique®: Following antisepsis of the perioral area, the physician placed the pad of the non-dominant index finger on the wet part of the red lip in front of the first marked point. A 30G needle was inserted through this point to reach the submucosal plane until the tip was 3 mm above the wet-dry red lip junction, as judged by the physician's index finger. Hyaluronic acid filler formulated with lidocaine was injected slowly at low pressure, with a maximum of 0.2 mL per medial point. The index finger inside the mouth felt the lump created under the mucosa by the filler and massaged the site to spread the filler along the major axis. The procedure was repeated for the upper lateral points and one on each side of the midline on the lower lip.

Product and volume

- RHA 2 • 1 mL

Needle and injection device

- Needle 30G 12 mm



PERIORAL RHYTIDS

Injection technique

- Blanching technique: Tiny aliquots of filler are placed intradermally by multiple punctures perpendicular to the wrinkle. Superficial filler injection results in white beads along the wrinkle that are smoothed out through post-injection massage⁷

Product and volume

- RHA 1 • 0.2 mL

Needle and injection device

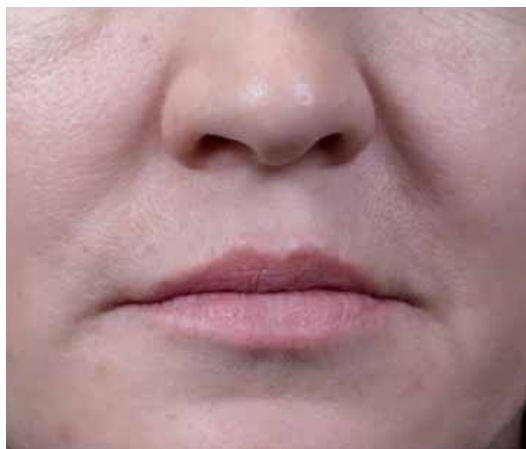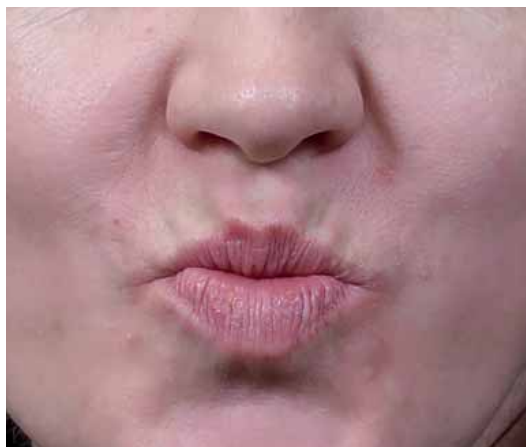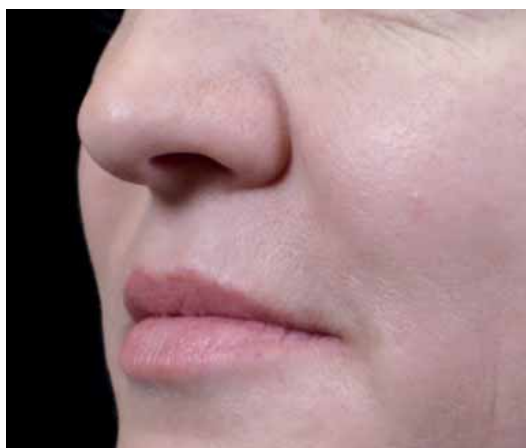- Needle 30G 13 mm

CASE 2

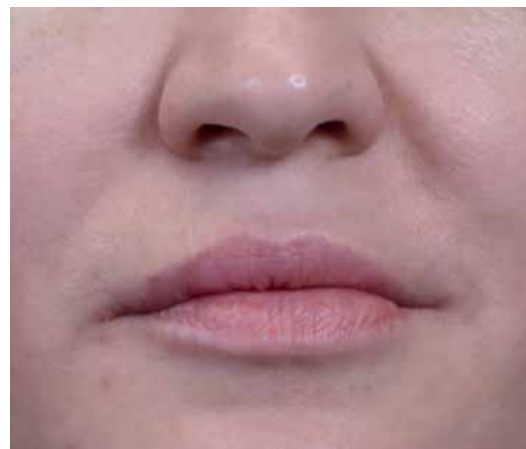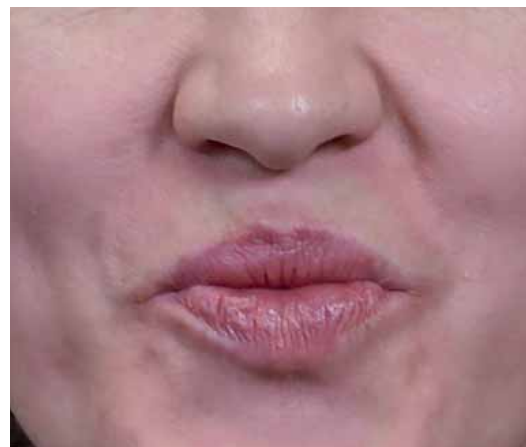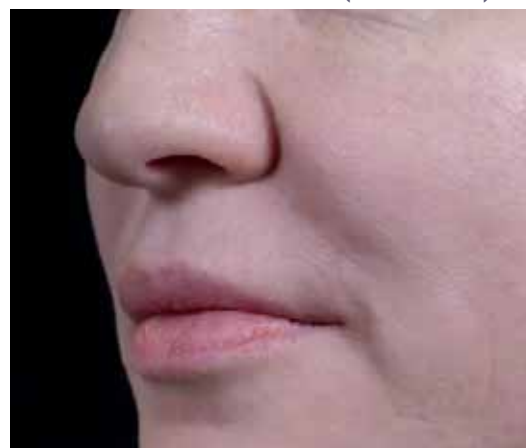Dr. Patrick Trévidic

RESULTS

BEFORE

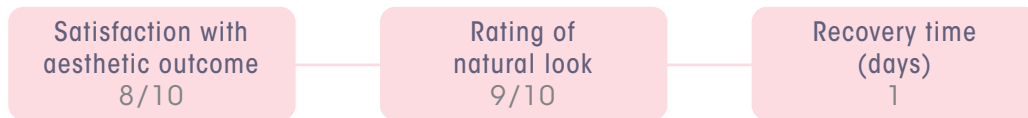

AFTER PROCEDURE (21 DAYS)





PATIENT FEEDBACK



The patient gave an overall rating of 10/10 and is willing to be injected with the same product again. She was satisfied with the improvement of her natural-looking lip eversion.

DR. RAYMOND WU



Dr Wu obtained his medical degree from the University of Hong Kong in 2006. He has strong interest in facial aesthetic injections. He has developed various unique injection techniques for different regions of the face. His skill and artistry with injectables is widely recognised and has led to him being appointed as an expert trainer and speaker by several injectable brands such as TEOXANE, Galderma, Dysport and Medytox. Over the past five years, Dr Wu has helped to train doctors all over South East Asia, sharing both his technical skills and his artistic aesthetic with hundreds of young practitioners. He is also a fellow of the Korean College of Cosmetic Surgery, faculty member of IMSA (International Microaesthetic Surgery Association), committee member of the Association of doctors in Aesthetic Medicine (ADAM) and the Hong Kong Medical Aesthetic Association (HKMAA).

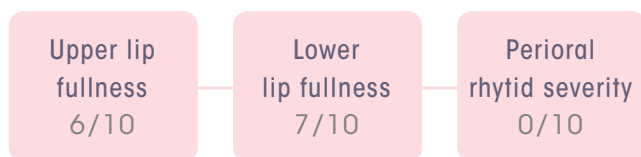PATIENT INFORMATION

Gender: Female
Ethnicity: Chinese
Age: 33 years old
Fitzpatrick skin type score: IV
Skin quality description (white and red lips):
Good quality
Previous treatment(s) in the perioral area:
None

PATIENT REQUEST

More defined vermillion border. Slightly fuller lips, especially upper lip. More lift around oral commissure.

BASELINE LIP EVALUATION



Static lip assessment: Upper lip lacking border definition and pearl-like protrusion of the upper lip (see number 3 on the injection diagram). Left lower lip slightly fuller than right. Slight downward turning of oral commissure.

Dynamic lip assessment: Muscle activity slightly stronger on right lower lip, which appears to roll more inward than left. Some rhytids on red lip, but none on white lip.

10-point scales were used to assess baseline lip evaluations and patient feedback.

PROTOCOL & INJECTION TECHNIQUES

Aim of treatment: Volumization of upper and lower lips, with greater focus on right lower lip. Increase definition of vermillion border.

Product of choice: RHA 3 for lip volumization and RHA 2 for vermillion border and upper lip pearl.

UPPER AND LOWER LIPS

The different injection points are indicated by numbered icons on the diagrams which correspond to the order of injection.

Location

1. Upper and lower lip
2. Vermillion border and Cupid's bow
3. Upper lip pearl
4. Oral commissure

Injection technique

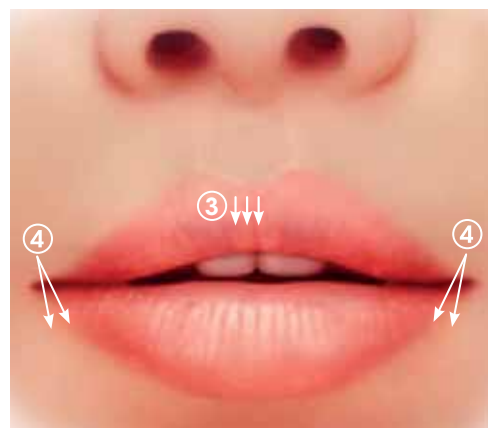
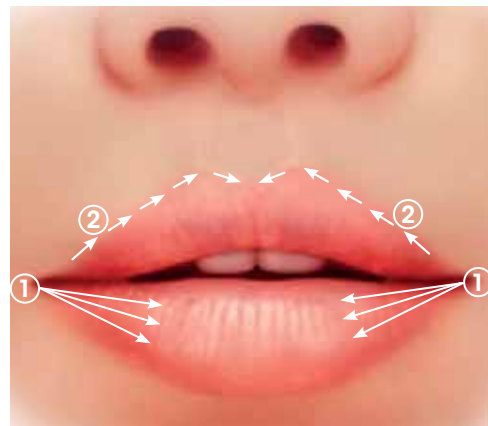
1. Linear threading (intramuscular)
2. Linear threading (subdermal)
3. Linear threading (subdermal)
4. Linear threading (subdermal)

Product and volume

1. RHA 3: 0.2 mL each side
2. RHA 2: 0.2 mL in vermillion border; 0.1 mL in Cupid's bow
3. RHA 2: 0.1 mL
4. RHA 2: 0.1 mL each side

Needle and injection device

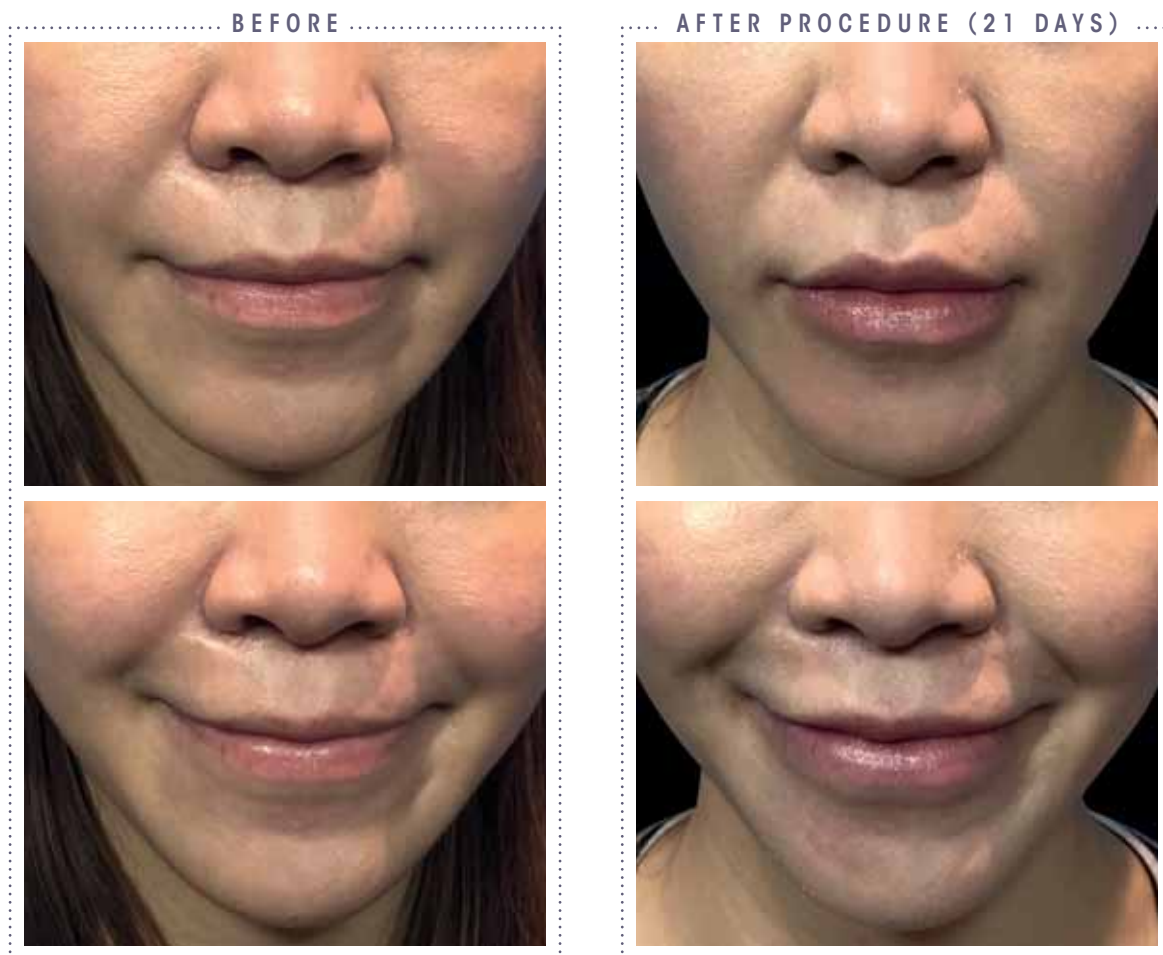1. Micro cannula 27G 40 mm
2. Needle 30G 12 mm
3. Needle 30G 12 mm
4. Needle 30G 12 mm



CASE 3

Dr. Raymond Wu

RESULTS



PATIENT FEEDBACK

Satisfaction with
aesthetic outcome
9/10

Rating of
natural look
9/10

Recovery time
(days)
1

"The product gave me exactly what I wanted. It is so natural that even my partner can't feel it."

PHYSICIAN FEEDBACK

The dynamic behaviour of RHA 2 and RHA 3 enables the injector to treat the lips in a multiplane fashion and yet maintain a natural outcome.

YOUR NOTES



A series of horizontal dotted lines for writing notes, spanning most of the page width.

DR. RAUL CETTO



Dr. Raul Cetto, MBBS, PhD, MRCS, DOHNS, PGCert, trained in Otolaryngology and Head and Neck Surgery at Imperial College Healthcare where he completed a PhD in the field. He subsequently specialized in non-surgical facial medical aesthetics by completing a post graduate Diploma in Aesthetic Medicine. He has trained in aesthetics with Dr Obagi (Beverly Hills) and practises at Clinic 1.6, in London.

He is actively involved in research on nasal airflow at Imperial College and to date has participated in multiple medical congresses internationally and authored several peer reviewed publications. Dr Cetto has been elected Associate Member of the British College of Aesthetic Medicine and is also a member of the European College of Aesthetic Medicine & Surgery. He is Medical Director of aesthetic training provider Harley Academy and is a medical board member for Swiss aesthetic manufacturer TEOXANE.

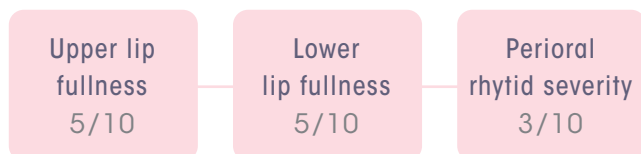PATIENT INFORMATION

Gender: Female
Ethnicity: Mixed Portuguese-African
Age: 45 years old
Fitzpatrick skin type score: V
Photo-ageing: Good, age appropriate.
Mild lentigo
Skin quality description (white and red lips):
Reduced skin elasticity
Previous treatment(s) in the perioral area:
None

PATIENT REQUEST

Enhancement of lip volume, definition and fullness.

BASELINE LIP EVALUATION



Static lip assessment: Loss of anterior projection on profile.

Dynamic lip assessment: Visible perioral rhytids on animation and loss of anterior projection when smiling.

10-point scales were used to assess baseline lip evaluations and patient feedback.

PROTOCOL & INJECTION TECHNIQUES

Aim of treatment: Volumization of both lips and eversion for a better anterior projection. Reduction of perioral rhytids by providing volume restoration and support in the lips.

Product of choice: RHA 3 for lip volumization and RHA 1 for vermillion border.

UPPER AND LOWER LIPS

The different injection points are indicated by numbered icons on the diagram which correspond to the order of injection.

Location

1. Paramedian line of the vermillion border
2. Lateral to oral commissure (1 cm) into body of lip anterior to wet and dry border

Injection technique

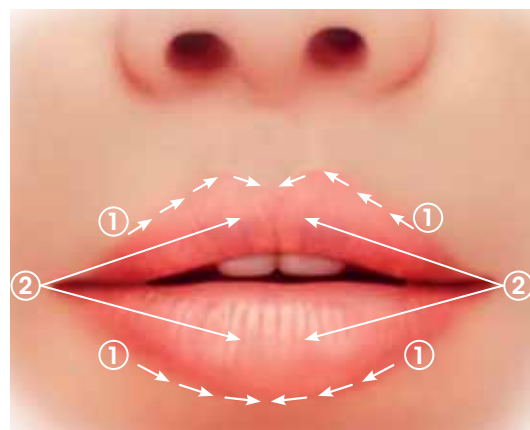
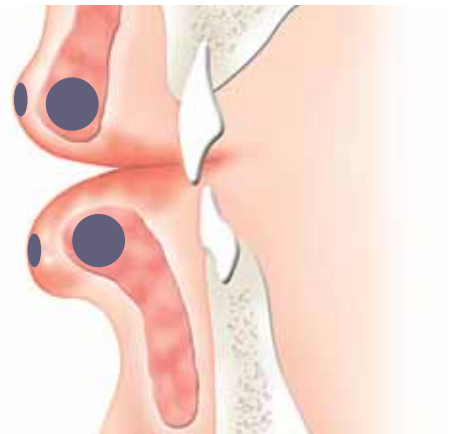1. Anterograde threading
2. Retrograde threading

Product and volume

1. RHA 1: 0.2 mL per lip per side (0.8 mL in total)
2. RHA 3: 0.2 mL per lip per side (0.8 mL in total)

Needle and injection device

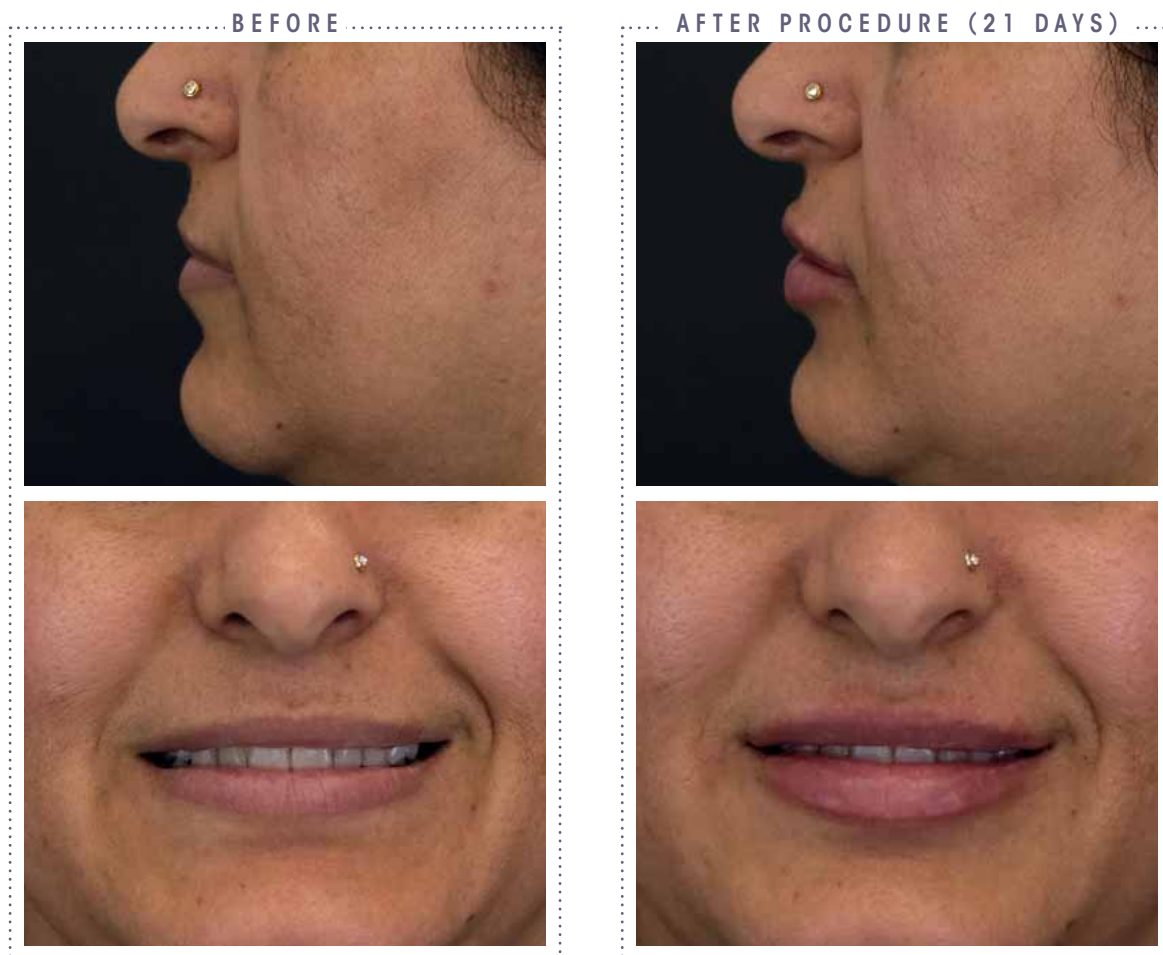
1. Needle 30G 4 mm
2. Cannula 25G 38 mm



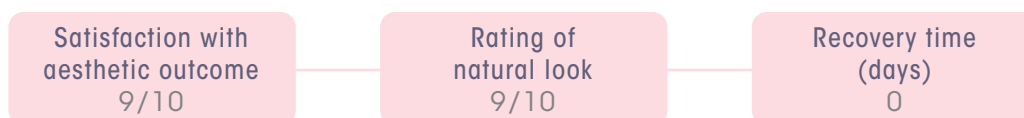
CASE 4

Dr. Raul Cetto

RESULTS



PATIENT FEEDBACK



There was no bruising nor swelling after injection; minor redness observed for 48 hours. No pain on recovery.

DR. RAUL CETTO



Dr. Raul Cetto, MBBS, PhD, MRCS, DOHNS, PGCert, trained in Otolaryngology and Head and Neck Surgery at Imperial College Healthcare where he completed a PhD in the field. He subsequently specialized in non-surgical facial medical aesthetics by completing a post graduate Diploma in Aesthetic Medicine. He has trained in aesthetics with Dr Obagi (Beverly Hills) and practises at Clinic 1.6, in London.

He is actively involved in research on nasal airflow at Imperial College and to date has participated in multiple medical congresses internationally and authored several peer reviewed publications. Dr Cetto has been elected Associate Member of the British College of Aesthetic Medicine and is also a member of the European College of Aesthetic Medicine & Surgery. He is Medical Director of aesthetic training provider Harley Academy and is a medical board member for Swiss aesthetic manufacturer TEOXANE.

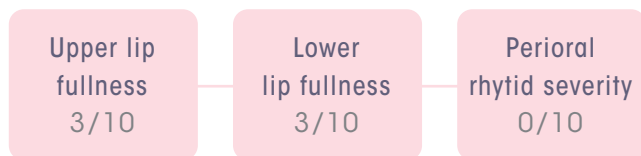PATIENT INFORMATION

Gender: Female
Ethnicity: Spanish
Age: 33 years old
Fitzpatrick skin type score: III
Photo-ageing: Lentigo
Skin quality description (white and red lips): Good, age appropriate. Acne
Previous treatment(s) in the perioral area: None

PATIENT REQUEST

Lip volume.

BASELINE LIP EVALUATION



Static lip assessment: Symmetrical, good shape, no projection from lateral view.

Dynamic lip assessment: Upper lip disappears showing no volume when smiling. No anterior projection of upper or lower lips.

10-point scales were used to assess baseline lip evaluations and patient feedback.

PROTOCOL & INJECTION TECHNIQUES

Aim of treatment: To add adequate volume and eversion of the lips.

Product of choice: RHA 3 for lip augmentation and RHA 2 for lip contouring.

UPPER AND LOWER LIPS

The different injection points are indicated by numbered icons on the diagram which correspond to the order of injection.

Location

1. Entry point 1 cm from oral commissure to access both upper and lower lips, into body of each lip anterior to wet and dry border
2. Paramedian line of the vermillion border

Injection technique

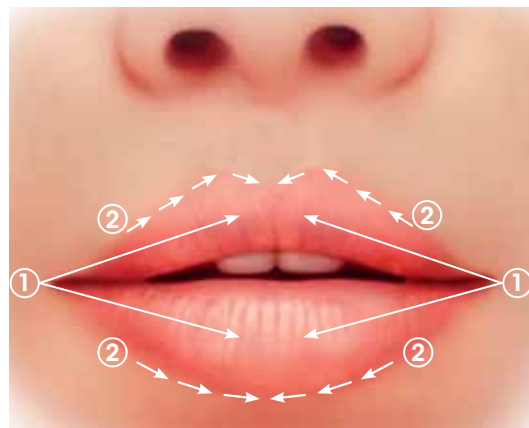
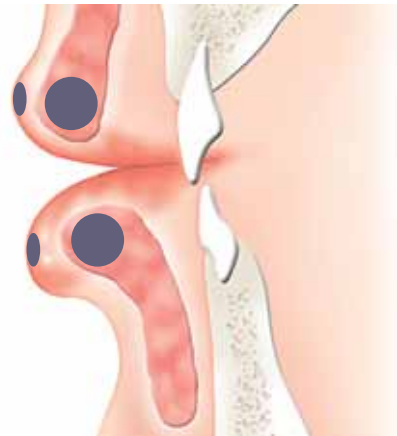1. Retrograde injection
2. Anterograde injection

Product and volume

1. RHA 3: 0.4 mL in each lip
2. RHA 2: 0.2 mL in each lip

Needle and injection device

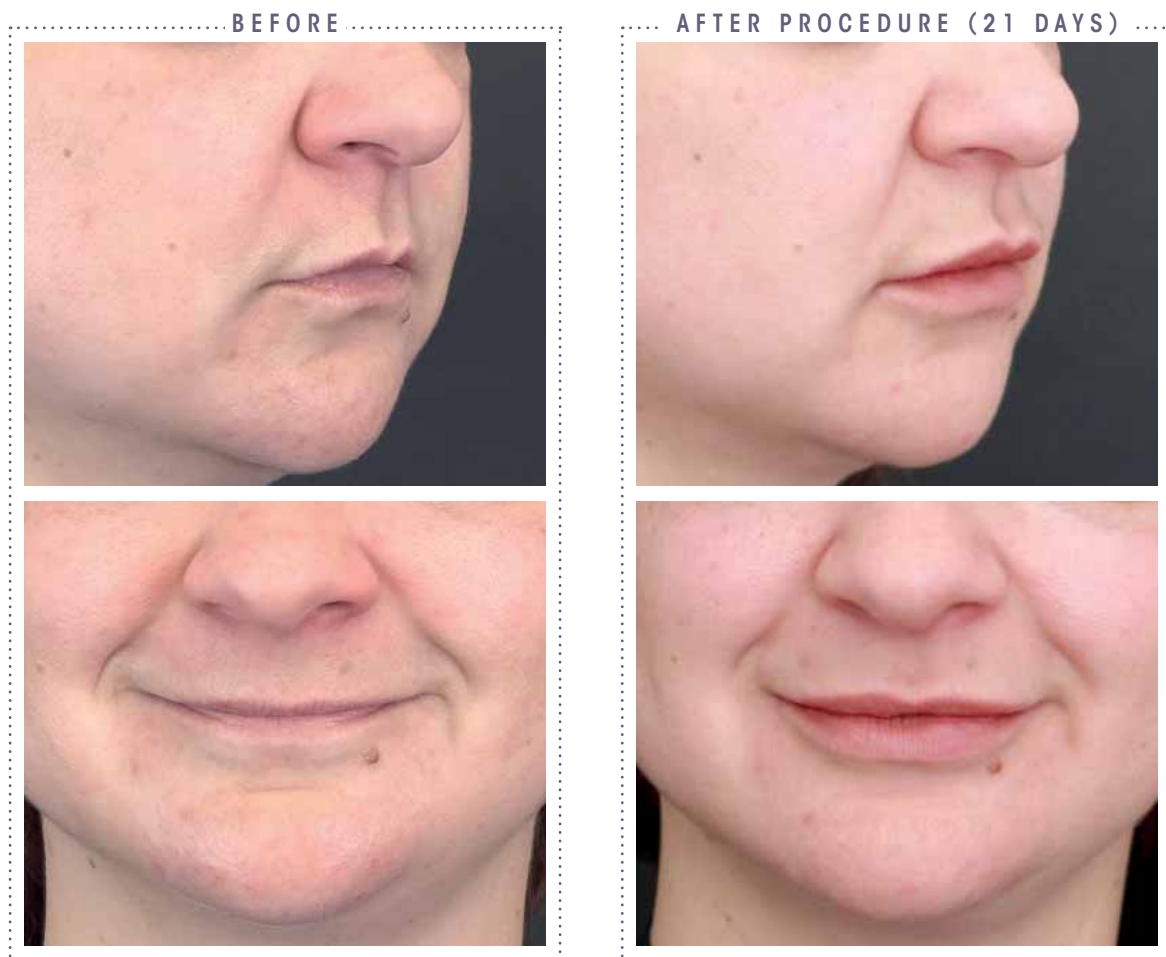1. Cannula 25G 38 mm
2. Needle 30G 4 mm




CASE 5

Dr. Raul Cetto

RESULTS



PATIENT FEEDBACK



The patient was extremely happy with her results. There was no bruising nor swelling after injection; minor redness observed for 48 hours. No pain on recovery.



A word from Madam Valérie Taupin

In today's world, beauty is no longer a question of age. Women want their beauty to last into the future and to reflect their personalities.

At TEOXANE Laboratories our focus has always been to be the global expert in the development of hyaluronic acids – keeping innovation, quality and safety at the heart of everything we do!



ree

Valérie Taupin
CEO & Founder,
TEOXANE

References

1. Michaud T, *et al. J Cosmet Dermatol.* 2015;14(1):9-21.
2. Sito G, *et al. Aesthet Surg J.* 2019. doi: 10.1093/asj/sjz026.
3. Micheels P, *et al. J Drugs Dermatol.* 2017;16(2):154-61.
4. Kenne L, *et al. Carbohydrate Polymers.* 2013;91:410-8.
5. DoF: RDRE 1906: RHA KISS® competitor study: mechanical properties of the products and packaging study-April 2019.
6. DoF: RDRE 1911: Rheological properties of the RHA products. July 2019.
7. Micheels P, *et al. Plast. Reconstr. Surg.* 2013;132:59S-67S.

Teoxane Australia
9 Cleg Street
Artarmon NSW 2064
teoxane.com.au

 [teoxane_australia](https://www.instagram.com/teoxane_australia)